



# Hip and Groin Pain in Physically Active Adults

A Formal ESSKA-EHPA-ESMA Consensus

**Chairmen:** Vikas Khanduja, Per Hølmich

**Consensus Advisor:** Philippe Beaufils

This brochure is a summary of the formal consensus on the hip and groin pain in physically active adults. It does not contain every statement, and some of the included content may be summarized.

To access the complete material of this project, please visit:  
<https://www.esska.org/page/Consensus>

#### GRADING DESCRIPTION

- *Grade A: high scientific level*
- *Grade B: scientific presumption*
- *Grade C: low scientific level*
- *Grade D: expert opinion*

## COMPOSITION OF STEERING GROUP

**Philippe Beaufils** (France)  
Consensus Projects Advisor

**Patricia Thoreux** (France)  
ESMA Chairperson

**Sufian Ahmad** (Germany)  
**Ustun Aydingoz** (Turkey)  
**Femi Ayeni** (Canada)

**Gian Luigi Canata** (Italy)  
**Francesco Della Villa** (Italy)  
**Lior Laver** (Israël)  
**Oliver Marin Pena** (Spain)  
**Hannu Paajanen** (Finland)  
**Theodora Papadopoulou** (United Kingdom)  
**Athanasios Papavasilou** (Greece)  
**Kristian Thorborg** (Denmark)  
**Adam Weir** (Netherlands)

## FELLOWS

**Nils Becker** (Germany)

**Junya Yoshitani** (Japan)

## PRESIDENTIAL FOREWORD

There is great variation across Europe when it comes to medical practice. Agreeing a common approach to pathologies or procedures has always been a challenge. But some such agreement is important, if we are to ensure standards. For years now, ESSKA has developed a strict and painstaking methodology which employs our considerable European expertise. We call it ESSKA European Consensus. Mixing scientific evidence and clinical expertise, this format aims to facilitate the dissemination of knowledge amongst the daily practitioners. One must underline the scientific value of such a project which should not be regarded as a simple expert opinion but as the result of a complex process based on high level scientific criteria such as pluralism (large European representativeness), iterative process and independence of the different involved groups.

Five ESSKA consensuses have already been delivered. More information is available on [www.esska.org/page/Consensus](http://www.esska.org/page/Consensus).


This year, at ESSKA 2024 Milan Congress, we are delighted to launch the ESSKA-EHPA-ESMA European Consensus on Hip and Groin Pain in Physically Active Adults.

We thank Vikas Khanduja and Per Hölmich - the Project leaders-, as well as Patricia Thoreux ESMA chairwoman, the members of the Steering, Rating, and Peer Review Groups for their tremendous efforts and dedication.

A special acknowledgement also for our staff, and particularly Mrs Anna Hansen Rak, without whom this would not have been possible.



**Roland Becker**  
ESSKA President  
2022-2024



**Joan Carles Monllau**  
ESSKA President  
2024-2026



**Philippe Beauflis**  
Consensus Projects  
Advisor

## CHAIRPERSON FOREWORD

Hip and groin pain are common in young and middle-aged active individuals and account for up to 10% of consultations in sports medicine. Pain-related limitations can result in significant functional losses.

A number of activity related injuries can result in pain in the groin region including muscle and tendon, inguinal canal, and hip joint. Epidemiologically at least 80% is related to the muscle and tendon problems but the inguinal and, from an orthopedic point of view, especially the hip joint has gained increased attention in recent years. The growth of hip preservation as an orthopaedic subspecialty aiming to prevent or delay the onset of degenerative changes in the hip, has seen a surge in recent years. More procedures are being performed and more surgeons, physiotherapists, sports medicine doctors and radiologists pursuing a career in this field. This underlines the importance of

this consensus rapport to inform about the differential diagnostics of hip and groin pain to be able to offer the right treatment for the right patient.

However, despite this growth, the terminology used to describe the diagnosis of hip and groin pain has previously been inconsistently used, resulting in the adoption of heterogeneous terms such as groin pain, athletic pubalgia, osteitis pubis and sports hernia.

The aim of the ESSKA EHPA-ESMA Consensus (in which five groups of experts: hip surgeons, sports medicine doctors, hernia surgeons, radiologists, and physiotherapists were involved) is to build a foundation for more precise communication, specifically in terms of terminology, clinical examination, and radiological investigations that one would request when presented with a young active adult with hip or groin pain.



**Vikas Khanduja**  
Chairperson



**Per Hølmich**  
Chairperson

## TERMINOLOGY AND CLASSIFICATION

### Which terminology and definitions for hip and groin pain in physically active adults are recommended?

Always consider the mechanism of injury, history, and pain pattern along with the clinical findings. It is important to note that the described clinical entities are not mutually exclusive, and multiple entities often co-exist.

Groin is defined as the junctional area between the torso and the anterior and medial thigh.

A clinical entity is used to identify a group of possible diagnoses, all related to a certain anatomical structure and connected by symptoms and specific clinical tests.

The terms adductor, iliopsoas, inguinal, pubic, and hip-joint related groin pain pathology should be used to describe the diagnosis of the common clinical entities of groin pain.

For hip joint-related groin pain the following terminology should be used to describe the diagnosis:

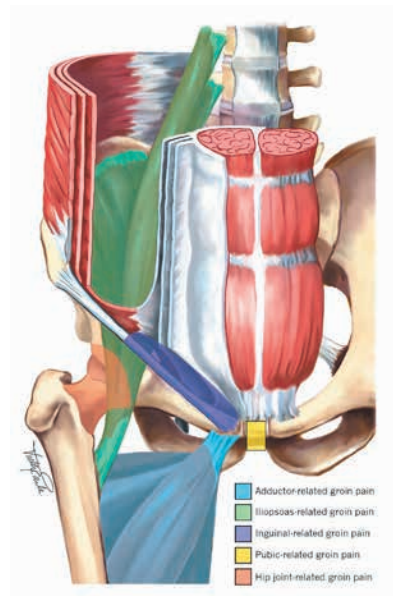
- Femoroacetabular impingement syndrome (FAIS)
- Acetabular dysplasia and/or hip instability
- Conditions with or without a distinct osseous morphology (viz: ligamentum teres pathology, labral, chondral pathology and/or subspine impingement)

The term 'morphology' should be used when describing cam and/or pincer impingement.

This list of clinical entities is not exhaustive and patients presenting with groin pain may also have symptoms arising from other sources (e.g. other muscles, tendons, bones, and nerves in that region).

Pain from non-musculoskeletal conditions and red flags should not be missed where possible. These should be considered, especially if symptoms cannot easily be classified into one of the commonly defined clinical entities for groin pain.

### Grade C



## CLINICAL EXAMINATION

### What clinical examination tests are recommended in physically active adults with hip and groin pain?

Clinical examination of patients with hip and groin pain needs to be interpreted in conjunction with medical history and imaging studies and/or diagnostic injections where appropriate to make a diagnosis.

A systematic clinical examination of the hip and groin should be performed in all cases. Following assessment of gait and Trendelenburg test, palpation and resistance testing of the adductors, iliopsoas, inguinal canal, and pubic symphysis should be carried out. The hip joint should be evaluated by assessment of range of movement and the FADIR test.

If there is recognizable groin pain on muscle resistance testing that can also be reproduced on palpation of that muscle/tendon, then extra articular muscle/tendons are a likely source. If hip joint ROM and the FADIR test are pain free, then hip joint related groin pain is unlikely. Conversely, if hip joint ROM testing

and the FADIR test are painful, the hip should be considered as a possible cause of groin pain.

Regarding hip instability, none of the frequently recommended tests have a high specificity.

The consensus group recommends to always consider rotational and/or version abnormalities of the femur and/or tibia and therefore range of movement of the hip should be performed in the prone position as well.

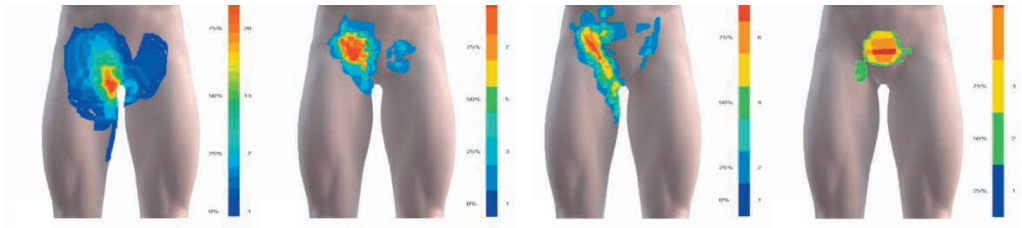
When young and active individuals present with groin pain it is important not to neglect the possibility of serious pathology (red flags). Especially if the clinical presentation does not fit with a common clinical entity like adductor, inguinal, iliopsoas, pubic or hip related groin pain.

It is common for a single patient to have pain arising from multiple clinical entities.

### Grade C

### Digital body mapping of pain quality and distribution in athletes with longstanding groin pain.

Serner, A., Reboul, G., Lichau, O. et al. *Sci Rep* 12, 9789 (2022).



## IMAGING

### Are diagnostic injections with local anaesthetic into the hip joint able to identify intraarticular pathology?

Pain relief obtained from a local I/A hip injection can reliably differentiate intraarticular pathology from extra-articular pathology

The local anaesthetic intra-articular hip injection should be guided by US or fluoroscopy.

The clinician should bear in mind that the diagnosis of hip pathology is formulated based on a patient's history, physical examination, imaging, and other supporting tests, which include local anaesthetic intra-articular hip injection. *Grade C*

### When is imaging indicated for physically active adults with hip and groin pain?

Findings on imaging do not necessarily correlate with hip and groin symptoms in physically active adults. Imaging should only be performed in symptomatic patients following a systematic clinical assessment. It should also be noted that symptomatic patients may

have normal imaging findings, and that many asymptomatic individuals have findings on imaging.

Current evidence does not support routine imaging screening for asymptomatic individuals.

Imaging provides morphometric analyses of the hip and pubic symphyseal joint and depicts the surrounding soft tissues. This can provide additional information on the suspected clinical condition and assist in planning optimal treatment.

Imaging should be considered when:

- There is clinical suspicion of underlying serious pathology.
- A patient with hip joint-related pain has not improved after a short course of non-surgical treatment.
- A patient with groin pain who does not respond to non-surgical treatment presents uncertainty of the clinical diagnosis.

*Grade C*



**In physically active adults with hip and groin pain, which imaging examinations are recommended as first line examinations? As second line examinations?**

Costs in terms of resource allocation (money, workforce, time) and the burden of ionizing radiation must always be taken into consideration prior to requesting investigations.

An adequate anteroposterior pelvic radiograph along with a Dunn view or similar lateral view is the first-line imaging examination for the morphological evaluation of the hip and groin.

If the suspected diagnosis is that of an inguinal hernia, the first-line imaging examination is ultrasonography.

MRI and CT are second-line investigations.

MRI or MR arthrography should be used for assessment of FAIS and acetabular dysplasia including femoral torsion (adding axial images

through the distal femur) and for assessing poor prognostic factors for hip preservation surgery (e.g., joint space narrowing, femoral or acetabular cysts, and bone oedema). MRI should also be used for assessing pubic-, iliopsoas- and adductor-related groin pain.

CT should be used with caution due to the ionizing radiation. However, low dose protocols are widely available and allow for 3D imaging of the hip which is useful for assessment and planning surgical resection in FAIS.

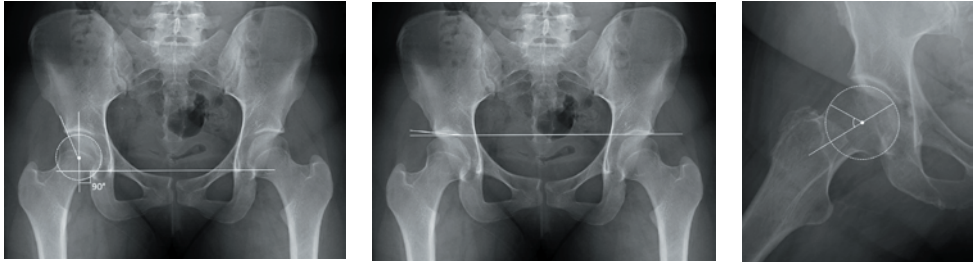
For adductor, inguinal or iliopsoas related groin pain ultrasonography can be utilised.

Finally, a diagnostic hip injection with local anesthetic under imaging guidance forms a second line investigation. Pain relief obtained from a local I/A hip injection can reliably differentiate intraarticular from extra-articular pathology.

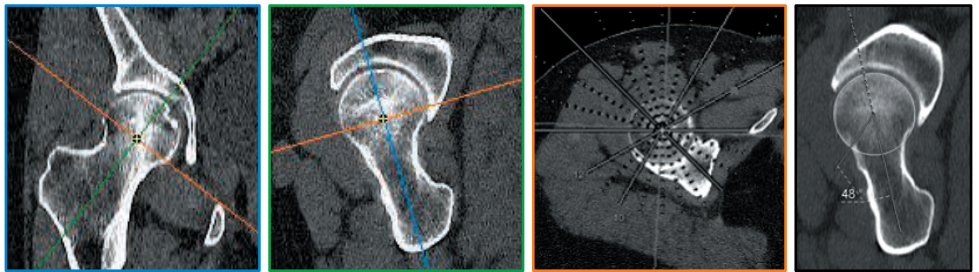
*Grade C*

## ANNEX : IMAGING MEASUREMENTS

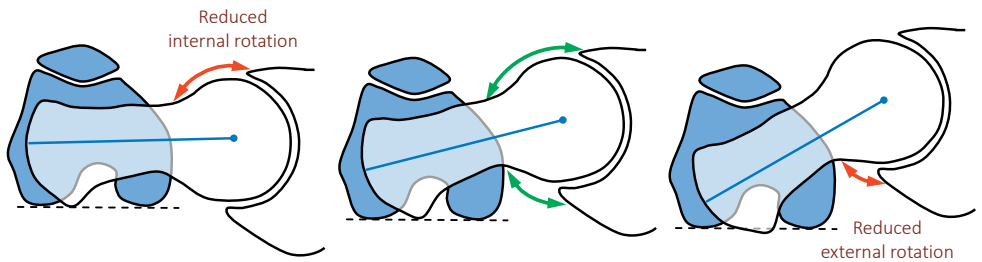
Measurement of the lateral central edge angle of Wiberg, Acetabular index and Alpha angle respectively.



Measurement of alpha angle on CT/MRI



Importance of measurement of femoral torsion in FAIS.



## ACKNOWLEDGEMENTS

To all members of the rating group: Emmanuel Audenaert (BE), Rintje Agricola (NL), Thor Einar Andersen (NO), Pedro Dantas (PT), Paul Dijkstra (QA), Cristiano Eirale (IT), Baris Kocaoglu (TR), Thoger Person Krogh (DK), Bent Lund (DK), Ajay Malviya (UK), Vasco Mascarenhas (PT), Jacek Mazek (PL), Vasileios Mitrousias (GR), Gilles Reboul (FR), Nicolas Reina (FR), Ernest Schilders (UK), Bertrand Tamalet (FR), Zarco Vukovic (RS), Michael Wettstein (CH), Tobias Wörner (SE).

We would also like to thank the peer reviewers from all over Europe for their contribution to this consensus.

## Contact Information

### **ESSKA Office**

Anna Hansen Rak

Project Manager

Phone: +352 4411 7026

Fax: +352 4411 7678

e-mail: [info@esska.org](mailto:info@esska.org)

[www.esska.org](http://www.esska.org)